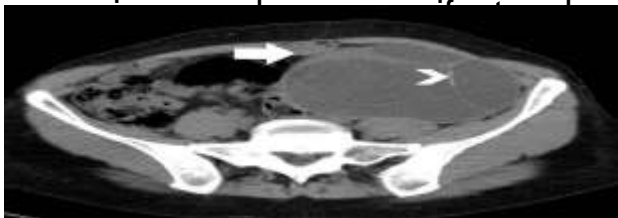


## INTRODUCTION

- Mucinous tumours are multiloculated cysts lined by epithelium resembling the endocervix
- They are referred to as pseudomucinous as its contents are not chemically true mucin
- Cut surface shows honey comb appearance
- Mucinous neoplasms of ovary account for 10-15% of ovarian neoplasm
- They may be benign ,borderline or malignant
- The large majority of are benign accounting for 80%,borderline accounting for 16-17% and malignant 5-10%.
- Mucinous neoplasms of the ovary most commonly affect women in their 20 to 40s
- Clinical manifestation is non specific ,but most mucinous neoplasms present with unilateral pelvic



## CONCLUSION

Mucinous cystadenoma of ovary if not intervened on time can be hazardous, leading to malignant mucinous carcinoma pseudomyxoma peritonei and significant morbidity and mortality.

## CASE STUDY

22years nulligravida with c/o severe lower abdominal pain since 1 1/2 month which was spasmodic in nature, on examination mass corresponding to 16 weeks of gestation with restricted mobility, cystic to firm in consistency, on p/v abdominopelvic mass corresponding to 16 weeks with posterior forniceal fullness with positive groove sign. On evaluations routine investigations and tumor markers like CEA ,CA 19-9 found to be normal. Usg suggestive of 10 \*10\*9 cm left ovarian cystic lesion noted in pelvis with multiple thin septa within it and CT scan shows large cystic lesion measuring 11\*11\*11cm seen in pelvis in midline showing septations thickness measuring <2mm

Diagnosis of left ovarian mucinous cystadenoma was made and patient was taken for laprotomy and cystectomy.

Laparotomy revealed large left multiloculated cyst arising from left ovary with blackish discolouration over the surface of cyst and anterior ,posterior surface of uterus, POD and omentum.

On cut section blackish fluid with septations seen

Specimen sent for histopathological examination and it is found to be benign mucinous cystadenoma of left ovary

Postoperatively patient was stable and discharged on day 7 and patient is stable now

