

CASE REPORT

INTRODUCTION-

Kartagener syndrome is a subgroup of primary ciliary dyskinesia (PCD) an autosomal recessive hereditary condition characterized by chronic sinusitis, bronchiectasis & situs inversus. The primary pathology is abnormal ciliary structure or function which results in decreased ciliary motility. In females might as well present with infertility and ectopic pregnancy.

A 41 year old female married for 15 years presented with recurrent respiratory infection and infertility. She had regular menstrual cycles, normal pelvic examination, blood reports and hysterosalpingography were normal. She had taken treatment for primary infertility several times in past. On further evaluation it was found that she had situs-inversus & bronchiectasis as well. Based on which diagnosis of KARTAGENER SYNDROME was made. Following this patient was referred to infertility center.

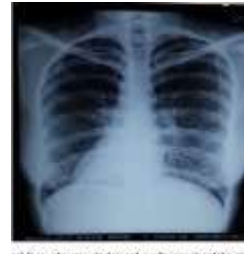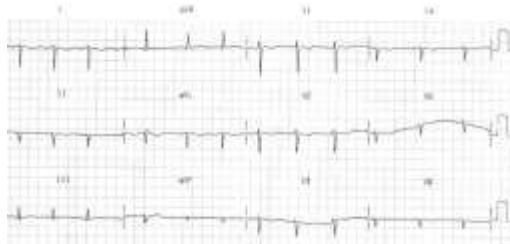
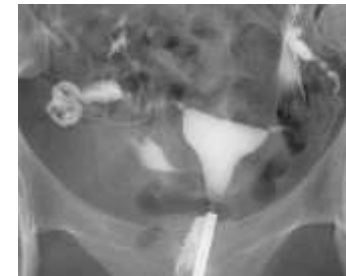

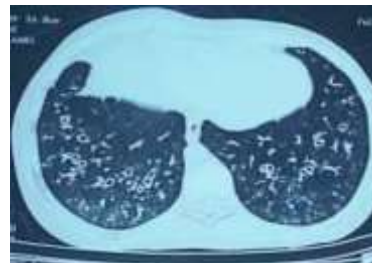
Fig. 1: X-ray of chest showing situs inversus totalis with situs inversus totalis



PROCEDURE- Transvaginal ultrasound revealed normal size uterus with 6 antral follicles in right ovary and 4 antral follicles in left ovary. Following which she underwent in vitro fertilization and frozen embryo transfer resulting in positive beta HCG test.

DISCUSSION- As a hereditary condition KS has no definite treatment. Patient management is symptomatic. Women with KS have low fertility rate, however there are cases of spontaneous conception reported, women presenting with primary infertility associated with chronic respiratory symptoms primary ciliary dyskinesia should be suspected.